

ViewPoint 6



GE Healthcare

Nancy L. Thyroid
34211 Central Ave
Boston 33221

Date: 11/8/2010

Soft Tissue Neck and Head Ultrasound

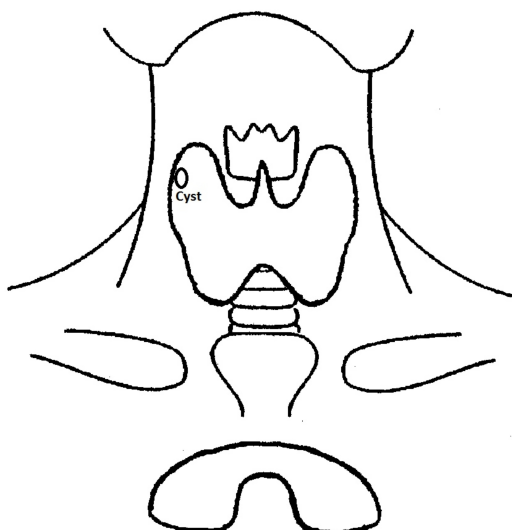
Indication Questionable right thyroid nodule.

Thyroid normal, no thyroid resection.

	RIGHT	LEFT
Vascularity	normal	normal
Size	normal	normal
Size	L/W/H: 5.5 cm x 3.0 cm x 2.8 cm	L/W/H: 5.8 cm x 3.2 cm x 3.1 cm
Vol.	24.2 cm ³	30.1 cm ³
Nodules	upper lateral. L/W/H: 1.00 cm x 0.50 cm x 0.70 cm. Mean: 0.73 cm. Vol.: 0.2 cm ³ . Structure: round, well defined, simple cyst.	

Isthmus The isthmus is within normal limits in size and configuration
AP: 0.7 cm. L: 2.5 cm.

Impression Small simple cyst seen in the upper right lobe.
The remainder of the thyroid is unremarkable. Normal thyroid sonogram.



B. Miller
Sonographer

Dr. B. Winter
Performing physician